

# Provision of a Mobile Uterine Artery Embolization Service to Medically Underserved Areas in Brazil

Nestor Kisilevzky, MD, and Henrique Elkis, MD

## ABSTRACT

**Purpose:** To determine the feasibility, efficacy, and safety of a mobile uterine artery embolization (UAE) program for patients in medically underserved, socioeconomically deprived areas.

**Materials and Methods:** One hundred women with symptomatic uterine leiomyomas were treated with UAE. A small truck containing a mobile c-arm and all needed supplies visited one hospital per week during a 6-month period. Four public hospitals were visited in rotation. Pre- and postprocedural magnetic resonance (MR) imaging and validated quality of life (QOL) questionnaires were obtained, and procedural details and complications were recorded.

**Results:** Technical success was achieved in 97 of 100 women. Mean procedure time was 41 minutes (range, 15–140 min) and mean fluoroscopy time was 17 minutes (range, 6–45 min). Mean hospital stay was 1.03 days (range, 1–3 d) and mean time to resumption of normal activities was 8.2 days (range, 2–20 d). At 12 weeks, 88% of patients noted symptomatic improvement and 98% stated they would recommend the procedure to other women. Complete tumor ischemia was seen on postprocedural MR imaging in 92% of women, with a mean uterine volume reduction of 36.3% (range, –4.3% to 65%) and a mean tumor volume reduction of 57.1% (range, –23.4% to 95.8%). Health-related QOL scores increased from 41.4 points before UAE to 81.2 points at 12 weeks and 85.3 points at 1 year after UAE. Complications were recorded in seven women (7%): three puncture site hematomas, three readmissions for pain control, and one case of leiomyoma passage.

**Conclusions:** A mobile interventional radiology unit is a feasible, efficient, and safe method to provide UAE to an underserved patient community. Outcomes and complications are similar to published results from centers with conventional angiographic facilities.

## ABBREVIATIONS

QOL = quality of life, UAE = uterine artery embolization

Since the first article describing uterine artery embolization (UAE) for symptomatic leiomyomas was published in 1995 (1), there has been much learned about this innovative treatment. Scientific articles published in the past 15 years led the American College of Obstetricians and Gynecologists to acknowledge uterine embolization as a safe and

effective alternative to hysterectomy based on level A (“good and consistent”) evidence (2).

In Brazil, UAE for leiomyomas has been offered for nearly a decade, with support of health insurers (3). As UAE requires skilled interventional radiologists and appropriate technology and resources, it is not widely available to Brazilian women of lower socioeconomic status. They receive their health care through public hospitals. Even in more developed regions of Brazil, such as the São Paulo metropolitan area, with an estimated population of 20 million, the public health care system is still responsible for providing services to almost half the inhabitants. Most of these people live below the poverty level, which prevents them from affording private health insurance or purchasing health care directly. The government has limited resources to invest in the public health care system and is unable to offer state-of-the-art technologies widely. Therefore, interventional radiology is less developed in the public system, with very few UAE programs available. Hysterectomy is the most common procedure for symptomatic uterine leiomyomas in the public health care system in Brazil.

From Hospital Israelita Albert Einstein, São Paulo, Brazil. Received July 18, 2010; final revision received December 7, 2010; accepted December 8, 2010. Address correspondence to N.K., Clínica Endovascular—Rua Guararapes, 682—Lapa, São Paulo, Brazil 05077-051; E-mail: kisilevn@uol.com.br

This study was funded by Instituto Israelita de Responsabilidade Social Albert Einstein, (São Paulo, Brazil). Materials for this study were donated or loaned by BioSphere Medical (Rockland, Massachusetts), Bayer-Schering (Berlin, Germany), and Philips Medical Systems (Best, The Netherlands).

Neither of the authors has identified a conflict of interest.

© SIR, 2011

*J Vasc Interv Radiol* 2011; 22:490–496

DOI: 10.1016/j.jvir.2010.12.012

To provide access to medical technology for patients with low incomes, the development of a mobile interventional radiology unit was proposed. The unit could be moved to different public hospitals in the São Paulo metropolitan area and provide UAE treatment for women with symptomatic leiomyomas. As we were aware of no published literature on such a subject, the purpose of the present study was to investigate the feasibility of an itinerant UAE service. Our hypothesis was that UAE can be provided safely and effectively via a mobile embolization unit to patients in medically underserved hospitals.

## MATERIALS AND METHODS

This prospective longitudinal study was approved by the research ethics committee of Hospital Israelita Albert Einstein. All patients included in this study signed an informed consent form. This study was funded by Instituto Israelita de Responsabilidade Social Albert Einstein (the philanthropic arm of Hospital Israelita Albert Einstein), covering expenses for personnel salaries (eg, nurse, driver, assistant), truck rental, radiologic table and protection aprons, angiographic and embolic supplies, magnetic resonance (MR) imaging studies, and logistics management. Half the embolic agents (microspheres) were donated by BioSphere Medical (Rockland, Massachusetts). All contrast medium was donated by Bayer-Schering (Berlin, Germany). The mobile c-arm was borrowed from Philips Medical Systems (Best, The Netherlands). Interventional radiologists (N.K. and H.E.) charged no fee.

One hundred patients with symptomatic uterine leiomyomas were treated by UAE between October 2008 and May 2009. The procedures were performed in four public hospitals in the São Paulo metropolitan area via the mobile interventional radiology unit, which was named ANGIOMOVEL. The unit consisted of a small truck to transport a mobile c-arm (BV Pulsera; Philips Medical Systems), a radiologic table, protection aprons, and trolleys containing supplies needed for angiographic examinations and embolization procedures. The team for the ANGIOMOVEL unit consisted of two physicians trained in interventional radiology (N.K. and H.E.), one nurse, one driver, and one assistant. Both interventionalists performing the procedures were very experienced, having performed 600 (N.K.) and 350 (H.E.) UAE procedures, respectively. Each participating hospital provided an operating suite or obstetric suite for use by the UAE team. At each session, the equipment was moved from the truck and a temporary angiographic suite was set up for the procedures (**Fig 1**). Twenty-one hospital visits were completed during the study, during which an average of 4.8 patients were treated (range, 3–8 patients per visit).

### Patient Selection

Patients were selected by the gynecologic team at each hospital based on a predefined study protocol (**Table 1**). They were not seen by an interventional radiologist before

the day of the procedure, but the interventional radiologists received clinical data and all MR images for evaluation in advance. All patients aged 25–50 years with symptomatic uterine leiomyomas, regardless of size, number, or location, were considered appropriate for inclusion. Patients were free of hormonal therapy within at least 6 months before the procedure. Pedunculated leiomyomas were not considered to represent a contraindication to UAE. Clinical and laboratory examinations had previously been performed, including MR imaging and a validated questionnaire (Uterine Fibroid Symptom and Quality of Life [QOL]) to determine the impact of symptoms on QOL (4,5).

The Uterine Fibroid Symptom QOL is a validated uterine leiomyoma-specific symptom and QOL questionnaire that is in broad use. It yields two scores, a symptom score and a QOL score; each are on a scale from 0 to 100, but are inverse. Higher symptom scores indicate worse symptom severity and higher QOL score indicates better QOL (4,5).

### Embolization Procedure

All procedures were performed under epidural anesthesia. A single right femoral artery puncture was used for vascular access through a 5-F sheath in all cases. A 5-F catheter (Cobra C2) was placed in the internal iliac artery. With the use of roadmapping for guidance, a microcatheter (Embo-cath; Biosphere Medical) was directed into the uterine artery. Tris-acryl gelatin microspheres (500–700- $\mu$ m Embosphere; Biosphere Medical) were used as the embolic agent and embolization was performed until a “pruned-tree” appearance was achieved (6–8). Nonionic contrast agent was used (Iopamiron 300; Bayer-Schering).

### Post-UAE Procedures

Patients remained hospitalized under the care of the gynecology team. After discharge, they were directed to the interventional radiology outpatient office at Hospital Israelita Albert Einstein, where the following variables were recorded: length of stay, time to resume activities after treatment, perception of symptoms, and level of satisfaction. Patients were also asked if they would recommend the procedure to other women.

### Follow-up

In accordance with the study protocol, all patients were asked to have an MR imaging study at 12 weeks after UAE to assess the degree of tumor necrosis and volume reduction of the uterus and dominant tumor(s). The QOL questionnaire was repeated and answers were compared with those obtained before UAE. In addition, outcomes and QOL were reviewed 1 year after UAE.

### Statistical Analysis

All data collected were input in an Excel (Microsoft, Redmond, Washington) worksheet for further analysis. Two-tailed paired Student *t* tests were performed to access



**Figure 1.** Logistics of mobile UAE unit. (a) The ANGIOMÓVEL truck arrives at a public hospital in the São Paulo metropolitan area. (b) The truck carries a portable c-arm, a radiologic table, protection aprons, and a trolley containing supplies. Equipment and supplies are unloaded into the hospital (c) and placed in the operation theater (d), where a procedure suite is temporarily prepared for embolization. (e) The procedure is performed with the c-arm in the in the operation theater. (Available in color online at [www.jvir.org](http://www.jvir.org).)

changes in uterine and tumor volume before and after UAE and a Fisher test was performed to assess changes in QOL from baseline to 12 weeks and 1 year after UAE. *P* values of less than .01 were considered statistically significant.

## RESULTS

The baseline demographic and clinical data of patients included in the study are presented in **Table 2**.

**Table 1.** Inclusion/Exclusion Criteria and Endpoints of the Study Protocol**Inclusion criteria**

- Symptomatic leiomyomas (abnormal bleeding, bulk, urinary frequency, pain, dyspareunia) regardless of size, number, or location
- Age 25–50 y
- Regular period and negative pregnancy test 7 d before inclusion
- No hormonal therapy  $\geq$  6 mo before inclusion
- Written informed consent
- Agreement to meet follow-up agenda (visits and examinations)

**Exclusion criteria**

- Inability to sign informed consent form
- Contraindication (eg, allergy, clotting disorder, renal insufficiency) to angiography with contrast medium
- Gynecologic symptoms not associated with leiomyomas
- Pregnancy
- Associated disease (adenomyosis, endometriosis, polyps)
- Gynecologic infection of any nature
- Pelvic malignancy
- Previous pelvic radiation therapy
- Concomitant liver failure, thrombophlebitis, or deep vein thrombosis
- Hemorrhagic stroke  $\leq$  6 mo before procedure
- Concomitant severe disease with life expectancy  $<$  2 y
- Sepsis
- Vascular lesion that precludes arterial catheterization

**Study endpoints**

## Primary endpoints

- Safety—adverse clinical outcome defined as intraoperative or immediate postoperative death (24 h)
- Efficacy—leiomyoma ischemia  $<$  70% assessed on postprocedure MR imaging
- Logistic—inviability of transporting and placing the mobile C arm in the hospital

## Secondary endpoints

## Safety

- Absence of major procedural related complications (before hospital discharge) including death, stroke, Q-wave myocardial infarction, bleeding requiring  $>$  2 U transfusion, or any other device- or procedure-related complication requiring unanticipated intervention or surgical procedure

## Efficacy

- Technical success—embolization of both uterine arteries (right and left) regardless of anatomic variations, demonstrated by the absence of blood flow to leiomyomas in the angiographic study
- Anatomic success—100% complete ischemic infarction of all leiomyomas regardless of uterine size, location, and quantity with the use of any of the four embolic agents used in the study
- Outcome success—relief or improvement of symptoms versus baseline on the scale of symptoms and appropriate QOL questionnaire that makes additional therapy unnecessary
- Procedure success—100% complete ischemic infarction of all leiomyomas regardless of size, location, and number and no significant adverse clinical events with hospitalization, defined as procedure-related death, Q-wave myocardial infarction, massive pulmonary embolism, sepsis, fatal allergic reaction, vascular dissection or rupture, distal embolism with tissue necrosis, or loss of the limb that underwent catheterization

**Procedure**

Technically successful bilateral UAE was achieved in 97 patients (97%). In two patients, only one uterine artery could be embolized, and in one patient, neither uterine artery was embolized. The mean procedure time was 40.8 min  $\pm$  19.4 (range, 15–140 min) and the mean fluoroscopy time was 17.5 min  $\pm$  8.5 (range, 6–45 min). The average volume of contrast agent used was 136.5 mL (range, 50–350 mL), and a mean of 3.1 vials  $\pm$  1.7 (2 mL) of embolic

microspheres was used (range, 0–10 vials). Ninety-eight of 100 patients (98%) were admitted to the hospital for 1 day. One patient stayed for 2 d and another for 3 d. The mean length of hospital stay was 1.03 d  $\pm$  0.22.

**Clinical Outcome**

The mean time to full resumption of activities after UAE was 8.2 d  $\pm$  3.6 (range, 2–20 d). Complications were recorded in seven patients (7%): three developed puncture

**Table 2.** Baseline Characteristics of the Population Included in the Study (N = 100)

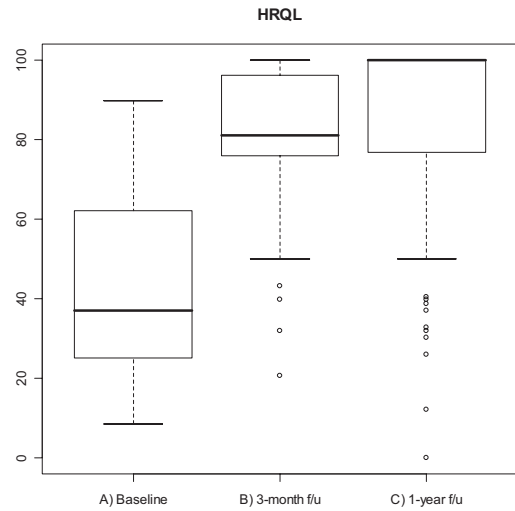
Characteristic	Value
Age (y)	
Mean	40.2 ± 6.7
Range	23–52
Median	41
Race	
White	48
Black	23
Mixed	29
Obstetric antecedents	
Nulliparas	34
Multiparas	66
Previous treatment	
Myomectomy	7
Hormonal therapy	24
Oral contraceptive pill	14
GnRH agonist	6
DMPA	4
Antiinflammatory therapy	52
Tumor-related symptoms	
Menstrual heavy bleeding	86
Abdominal distension	72
Pelvic pain	61
Pelvic discomfort	74
Back pain	37
Dyspareunia	68
Urinary problems	49
Number of tumors	
Single	24
Multiple	76
Uterine volume (cm <sup>3</sup> )	
Mean ± SD	454.8 ± 333.4
Range	128–1,950
Dominant tumor volume (cm <sup>3</sup> )	
Mean ± SD	155.3 ± 221.7
Range	2.6–1,460

Note.—DMPA = depot medroxyprogesterone acetate; GnRH = gonadotrophin-releasing hormone.

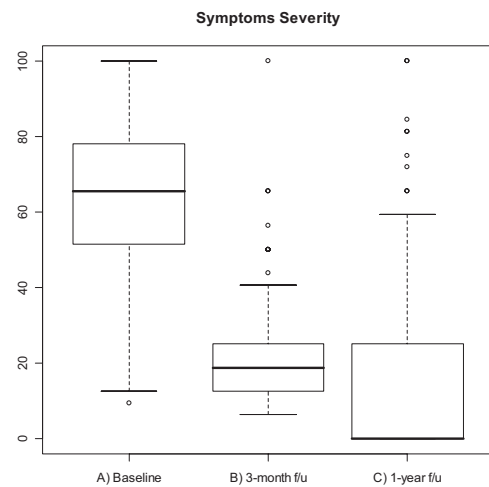
site hematoma with no need for further therapy and four required readmission, three for pain control and one for leiomyoma passage.

At 12-week post-UAE clinical follow-up, 88 patients reported symptom improvement and 10 reported unchanged symptoms. Seventy-eight patients were very satisfied, 18 were satisfied, and four were not satisfied with their treatment. Ninety-eight patients (98%) stated they would recommend the procedure to other women.

On the QOL questionnaires, the mean score recording the severity of symptoms decreased from 62.0 ± 20.9 before UAE to 22.5 ± 15.9 after UAE (*P* < .001). The QOL score increased from 41.4 ± 22.0 before UAE to 81.2 ± 16.1 at 12 weeks after UAE (*P* < .001).



Moment(n87)	Minimum	P25	Mean	Median	P75	Maximum	SD
A) Baseline	8.6	25	41.4	37.1	63.8	89.7	22
B) 3-month f/u	20.7	75.9	81.2	81	96.6	100	16.1
C) 1-year f/u	0	75.9	85.3	100	100	100	24.9



Moment (n87)	Minimum	P25	Mean	Median	P75	Maximum	SD
A) Baseline	9.4	50	62.0	65.6	78.1	100	20.9
B) 3-month f/u	6.3	12.5	22.5	18.8	25	100	15.9
C) 1-year f/u	0	0	17.0	0	25	100	26.7

**Figure 2.** Changes in QOL scores assessed through a validated questionnaire in 87 patients.

Eighty-eight patients (88%) were seen at 1-year follow-up. Symptoms had improved in 79 of these patients (89.8%), were unchanged in six (6.8%), and had worsened in three (3.4%). Three patients had undergone hysterectomy as a result of symptom recurrence. One patient had developed permanent amenorrhea. Of nine patients who attempted conception, one became pregnant, resulting in caesarian delivery at 37 weeks. At 1 year after UAE, the QOL questionnaire in 87 patients showed a mean symptom se-

**Table 3.** Comparison of Uterine and Dominant Leiomyoma Volumes (cm<sup>3</sup>) before and after UAE (N = 100)

Volume	Mean ± SD	Median	Range	P Value
Uterine volume				
Before UAE	454.8 ± 333.4	325	128–1,950	<.001
After UAE	281.7 ± 211.2	209.5	72.3–1,500	
Dominant tumor volume				
Before UAE	155.5 ± 221.7	66.8	2.2–1,460	<.001
After UAE	78.1 ± 155.5	21	1.6–1,257	
Size reduction (%)				
Uterus	36.3 ± 13.8	36.1	–4.3 to 64.9	–
Tumor	57.1 ± 25	60.2	–23.4 to 100	–

verity score of  $17.0 \pm 26.7$  ( $P < .001$  vs before UAE) and a mean QOL score of  $85.3 \pm 24.9$  ( $P < .001$  vs before UAE; **Fig 2**).

### MR Imaging

All patients underwent an MR imaging study 12 weeks after UAE. Complete tumor ischemia was demonstrated in 92 patients (92%). The mean uterine volume decreased from  $454.8 \text{ cm}^3$  (range, 128–1,950 cm<sup>3</sup>) before treatment to  $281.7 \text{ cm}^3$  after UAE (range, 72.3–1,500 cm<sup>3</sup>), a mean reduction of 36.3%. Mean leiomyoma volume decreased from  $155.5 \text{ cm}^3$  (range, 2.6–1,460 cm<sup>3</sup>) before UAE to  $78.1 \text{ cm}^3$  (range, 1.6–1,257 cm<sup>3</sup>) after UAE, representing a 57.1% reduction (**Table 3**). Additional MR images demonstrated total elimination of submucosal leiomyomas in five patients.

### DISCUSSION

Uterine embolization has gained wide acceptance as a first-line therapy for uterine leiomyomas (5–10). The objective of the present study was to present the concept of a mobile UAE service and demonstrate that similar outcomes to those described in the literature can be achieved with this service.

Very few public hospitals in the São Paulo metropolitan area provide interventional radiology services, and even fewer routinely offer uterine embolization. According to the Brazilian Institute of Statistics and Geography, there are almost 5 million women 20–49 years of age old living in the São Paulo metropolitan area (11). Many of these women already have or will develop symptomatic uterine tumors, and half of them depend exclusively on health care programs offered by the public system, in which hysterectomy is the most disseminated therapy. Our hypothesis was that we could help to modify this current scenario by introducing UAE technology into those underserved communities. The concept of a mobile health unit is not new and has been reported in diverse fields of medicine (12–14). However, to the authors' knowledge, a portable interventional radiology service had not previously been described.

The intent was to establish the safety and efficacy of performing the procedure on patients on an itinerant basis and where aftercare is monitored remotely. Objective measurement of UAE, complete tumor ischemia as assessed on MR imaging, and subjective measurement of symptom improvement via validated questionnaires were used to assess clinical efficacy. The results obtained are consistent with those reported in the literature: the symptom and QOL scores 1 year after therapy in the FIBROID Registry (15) were  $19.2 \pm 17.9$  and  $86.6 \pm 18.1$ , respectively, which are similar to those obtained in our experience.

The guidelines prepared and published by the Society of Interventional Radiology recommend a technical success threshold of 96% for UAE when the procedures are performed in a conventional angiographic room with fixed digital angiography equipment (16). We were able to meet this recommendation while working with portable equipment. An important factor to consider in UAE is pelvic radiation exposure, with its potential for negative impact on ovarian function. This is directly related to fluoroscopy time. Previously published studies indicate a mean safe radiation time of approximately 20 minutes, which may be similar to those used in hysterosalpingography or fallopian tube recanalization (17,18). With the portable unit, we were able to achieve fluoroscopic times within an acceptable range.

Postembolization complications are well described and are generally infrequent and not severe (19). The complication profile described in our patient group was similar to published results.

Finally, we believe this endeavor has added to the broad concept of interventional radiologists as health care professionals. In the authors' opinion, it is socially responsible to direct our expertise and a portion of our working time to benefit those who have no access to advanced medical procedures. This can only serve to reinforce the identity and profile of interventional radiology.

The itinerant UAE program with a mobile unit described here is a feasible, efficient, and safe means of providing treatment in institutions that would not normally have this technology. It is a socially responsible alternative

method to provide access to state-of-the-art technology to socioeconomically deprived patients.

## REFERENCES

1. Ravina JH, Herbreteau D, Ciraru-Vigneron N, et al. Arterial embolisation to treat uterine myomata. *Lancet* 1995; 346:671–672.
2. ACOG Practice Bulletin. Alternatives to Hysterectomy in the Management of Leiomyomas. Number 96, August 2008. *Obstet Gynecol* 2008; 112:387–400.
3. Kisilevzky NH, Martins MS. Embolização uterina para tratamento de mioma sintomático: experiência inicial revisão da literatura. *Radiol Bras* 2003; 36:129–140.
4. Kisilevzky N. Embolização uterina para tratamento de miomas sintomáticos: impacto na qualidade de vida. *Radiol Bras* 2007; 40:289–296.
5. Spies J, Coyne K, Guaou G, et al. The UFS-QOL, a new disease-specific symptom and health-related quality of life questionnaire for leiomyomata. *Obstet Gynecol* 2002; 99:290–300.
6. Pelage JP, Le Dref O, Beregi JP, et al. Limited uterine artery embolization with tris-acryl gelatin microspheres for uterine fibroids. *J Vasc Interv Radiol* 2003; 14:15–20.
7. Smith WJ, Upton E, Shuster EJ, Klein AJ, Schwartz ML. Patient satisfaction and disease specific quality of life after uterine artery embolization. *Am J Obstet Gynecol* 2004; 190:1697–1703.
8. Lohle PN, Boekkooi FP, Smeets AJ, et al. Limited uterine artery embolization for leiomyomas with tris-acryl gelatin microspheres: 1-year follow-up. *J Vasc Interv Radiol* 2006; 17:283–287.
9. Pinto I, Chimeno P, Romo A, et al. Uterine fibroids: uterine artery embolization versus abdominal hysterectomy for treatment: a prospective, randomized, and controlled clinical trial. *Radiology* 2003; 226:425–431.
10. Spies JB, Cooper JM, Worthington-Kirsch R, Lipman JC, Mills BB, Benenati JF. Outcome of uterine embolization and hysterectomy for leiomyomas: results of a multicenter study. *Am J Obstet Gynecol* 2004; 191:22–31.
11. Instituto Brasileiro de Geografia e Estatística. Available at <http://www.ibge.gov.br>. Accessed September 29, 2010.
12. Oriol NE, Cote PJ, Vavasis AP, et al. Calculating the return on investment of mobile healthcare. *BMC Med* 2009; 7:27.
13. Naeim A, Keeler E, Bassett LW, Parikh J, Bastani R, Reuben DB. Cost-effectiveness of increasing access to mammography through mobile mammography for older women. *J Am Geriatr Soc* 2009; 57:285–290.
14. Portnoi LM, Dibirov MP, Denisova LB. Diagnostic perspectives of mobile radiographic computerized tomography. *Vestn Rentgenol Radiol* 1992; 4:44–48.
15. Spies JB, Myers ER, Worthington-Kirsch R, Mulgund J, Goodwin S, Mauro M; FIBROID Registry Investigators. The FIBROID Registry: symptom and quality-of-life status 1 year after therapy. *Obstet Gynecol* 2005; 106:1309–1318.
16. Hovsepian DM, Siskin GP, Bonn J, et al. Quality improvement guidelines for uterine artery embolization for symptomatic leiomyomata. *J Vasc Interv Radiol* 2004; 15:535–541.
17. Andrews RT, Brown PH. Uterine arterial embolization: factors influencing patient radiation exposure. *Radiology* 2000; 217:713–722.
18. Nikolic B, Spies JB, Lundsten MJ, Abbara S. Patient radiation dose associated with uterine artery embolization. *Radiology* 2000; 214:121–125.
19. Spies JB, Spector A, Roth AR, Baker CM, Mauro L, Murphy-Skrzynarz K. Complications after uterine artery embolization for leiomyomas. *Obstet Gynecol* 2002; 100:873–880.